

CHRONICLE MONTHLY

APRIL 2020: VOLUME 15, EDITION 4



APRIL IS

**ORAL CANCER
AWARENESS
MONTH** 

oralcancerfoundation.org

~53,000 people in the US will be newly diagnosed this year

REMINDERS

SEEKING SUBMISSIONS! ★

⇒ Submit stories for **SAVE YOUR TOOTH MONTH**

⇒ Submit any and all photos

⇒ **Earth Day** is April 22

CONTACT

aawdchronicle@gmail.com

[@womendentists](https://www.instagram.com/womendentists)

www.aawd.org

HEY LADY DENTIST!

We hope you and your loved ones are staying safe and healthy. Read below for some fun as we all continue to social distance.

SAVE THE DATE!

WE ARE ONE YEAR FROM OUR 2021 ANNUAL MEETING
AAWD IS PROUD TO PARTNER WITH SMILES AT SEA FOR
OUR 100TH BIRTHDAY.



We want to see our members in their

ARMOIRE

@armoirstyle

#myarmoirstyle

TRY OUR ORAL PATHOLOGY QUIZ!

51-year-old male

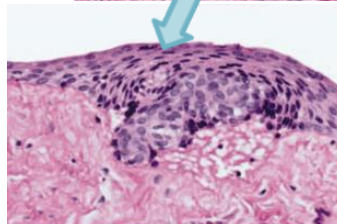
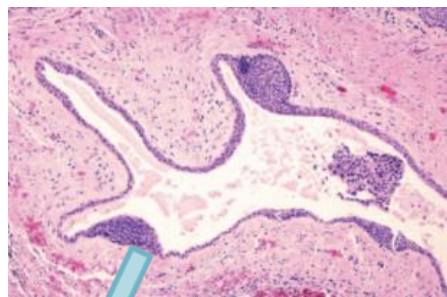
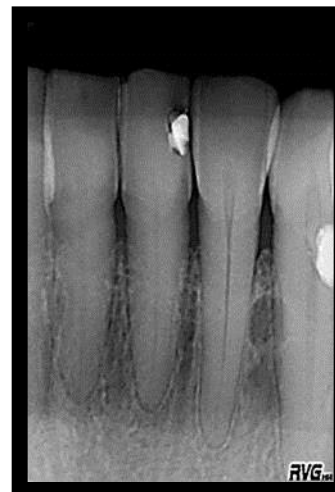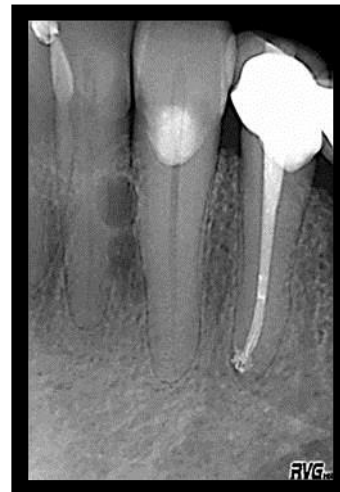
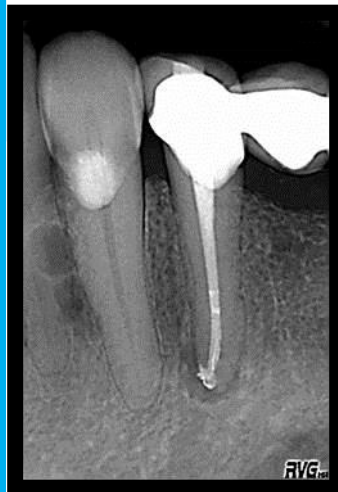CC: none

IOE: painless, well-circumscribed, slight swelling of gingival mucosa between #22-23, hard to palpation and covered by normal mucosa

Pulp tests: #22 & 23 responded brief, non-lingering to cold

PA: multiple, well-circumscribed, radiolucent, unilocular lesions within the mandible laterally between the roots of #22-23, corticated borders, and measuring ~0.5cm in diameter with slight divergence of roots.

Histology: Cystic cavity lined by simple squamous epithelium with clear cells and no inflammatory cells.



APRIL IS ORAL CANCER
AWARENESS MONTH.
LET'S SPREAD THE WORD -
GET CHECKED!



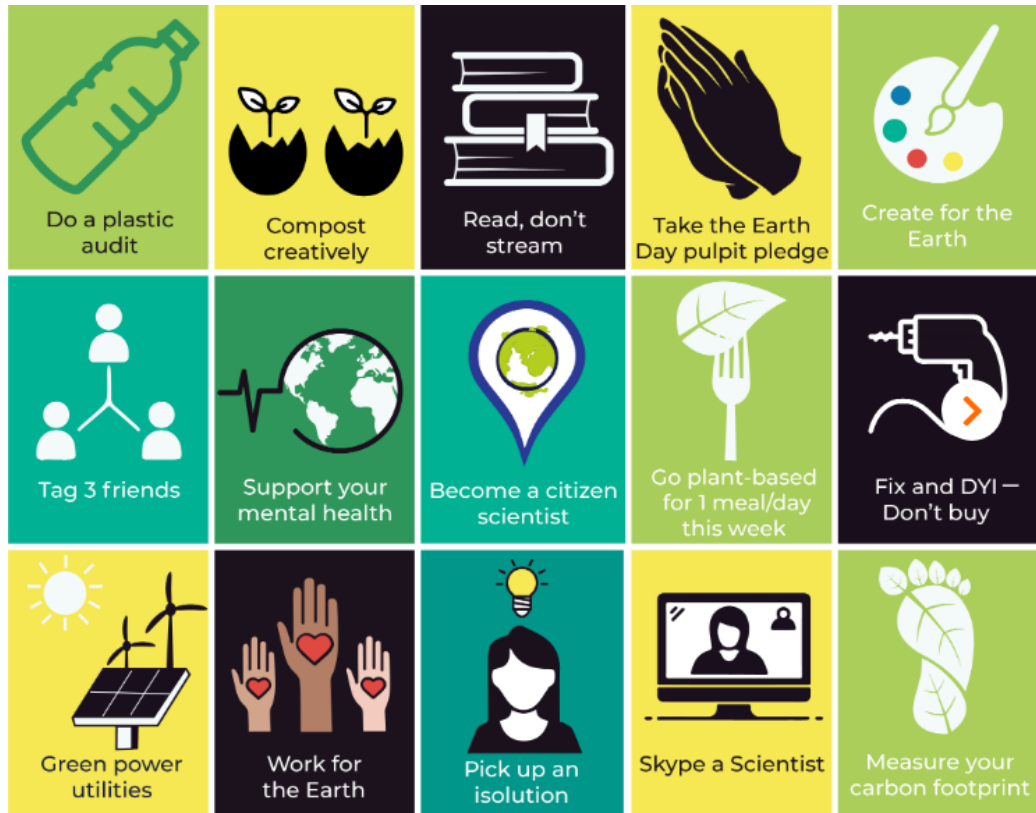TEST YOURSELF!

- A. Lateral radicular cyst
- B. Lateral periodontal cyst
- C. Neurofibroma
- D. Keratocystic odontogenic tumor (KCOT)

(Scroll to the end for the answer)

Want to be featured in the Chronicle Monthly?
Email submissions to aawdchronicle@gmail.com

MAKE EVERY DAY EARTH DAY



CHECK OUT OUR PARTNERS:



EARTH DAY IS APRIL 22 – Challenge yourself to make small changes.
www.earthday.org



We want to see how you've been social distancing!

Be sure to check our Facebook group for recipes, crafts, and conversation. Feel free to submit!



Use #quaranQUEEN and tag @womendentists to be featured on our social media and next edition of the Chronicle Monthly!

Oral pathology quiz answer:
B – Lateral periodontal cyst of the botryoid type.