

SAVE

YOUR

TOOTH

MONTH

MAY 2020

WWW.AAE.ORG

REMINDERS SEEKING SUBMISSIONS!

- ⇒ AAWD AWARD SEASON STARTS 5/25
- ⇒ SUBMIT PHOTOS
- ⇒ JUNE IS PRIDE MONTH
- ⇒ WEBINAR JUNE 2 / 8PM EST

CONTACT

aawdchronicle@gmail.com

@womententists

www.aawd.org



CHRONICLE MONTHLY

MAY 2020: VOLUME 15, EDITION 6

HEY LADY DENTIST!

We hope you and your loved ones are staying safe and healthy. Read below for some fun as we all continue to social distance.



EARLY BIRD REGISTRATION ENDS 5/16

SAVE YOUR TOOTH MONTH: ENDODONTIC CASE

Clinical Exam:

10-year-old Caucasian male

NCMH, No meds, NKDA

Healthy 4th grader who likes to play video games

CC: "My tooth is a different color now."

Dental History:

11/2014 Trauma #8 – luxation injury

"Tooth became loose & splinted for 2 weeks"

03/2015 Pulpal Regeneration/Apexogenesis

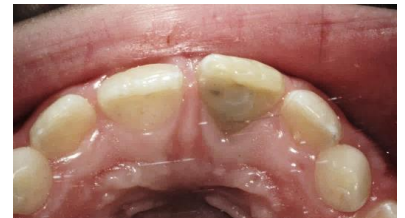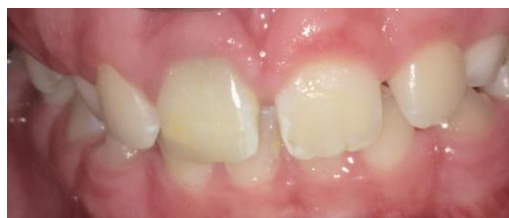08/2015 Sinus tract and symptomatic to percussion

10/2015 Apexification

08/2017 22-month recall with discoloration

10/2017 Internal bleaching completed

Shade C3 → B2 over 4 weeks



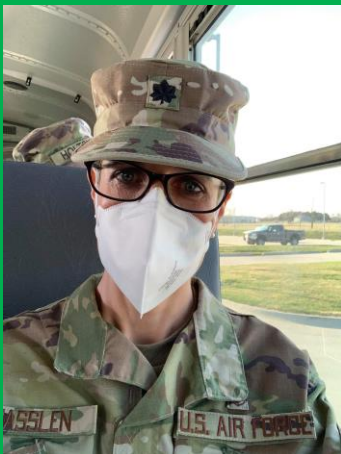Case Continues on Pages 3 & 4

Member Spotlight: Dr. Jenn Hasslen

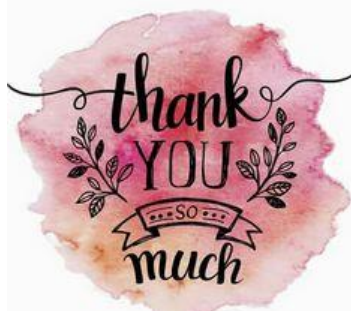"If you would have told me a year ago that I would be placing a swab 3-4 inches into someone's nasal passage to reach the nasopharynx, I would have told them they were crazy. But, that's just what I have been doing for the better part of almost 5 weeks now. In early April, many members of the 155th Air National Guard Medical Group based in Lincoln, Nebraska were activated. We were needed by our state to assist in wide-spread testing for COVID-19, as were countless other National Guard members around the country to help with testing, food banks, and other missions.

I kind of hate to say it's been fun, but my team of Army and Air Force National Guard members is awesome, and even just some patient interaction has been great. One woman, after I pulled the swab out of her nose after 10 seconds of twisting it around, stated that it was like going to the dentist! "Well, Ma'am, funny you should say that," is all I said. This is certainly easier than a Gow-Gates block, but the patient-provider experience is very real as some are incredibly nervous about having this done. A positive test can very easily be life changing in many ways, and a little kindness and compassion goes a long way to calming their fears.

The experience is surreal to say the least, but we've all been dealing with so much that isn't normal, it's hard to say what we can expect from day to day anyway. I will do this for a little over 6 weeks while wearing all the appropriate PPE. I will get tested (possibly by myself?) toward the end of my time on duty and return to my jobs at the dental school and office. I know everything is going to look different upon my return. At least I've accustomed myself to the less than ideal breathability of those N95s!"



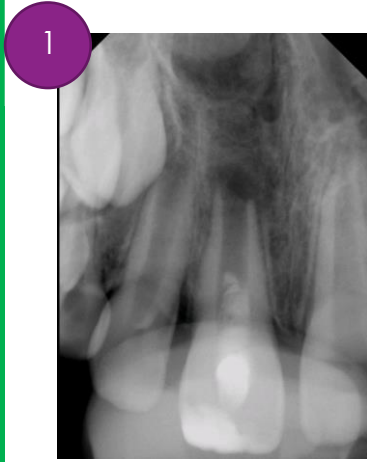Dr. Hasslen – Thank you for your dedication and for your work on the frontlines during this challenging time. –AAWD BOD



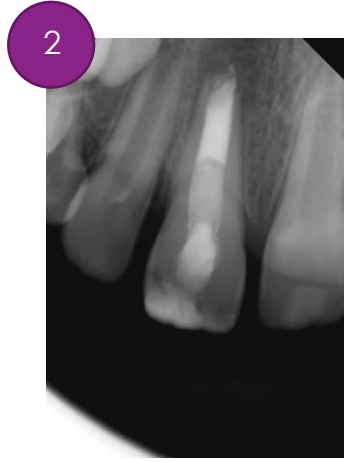ENDO CASE CONTINUED:

**WORTH
SAVING**

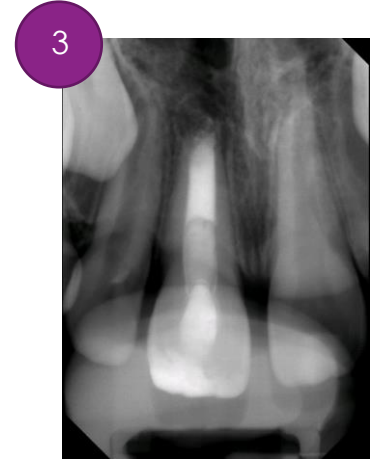AMERICAN ASSOCIATION
OF ENDODONTISTS



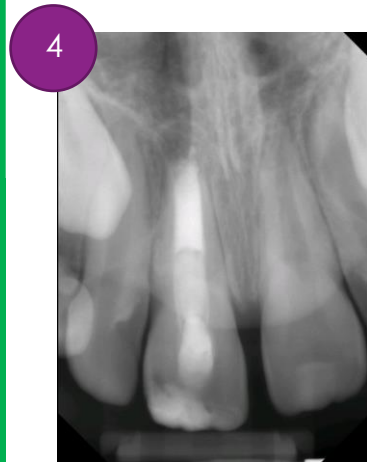
08/2015 –
Nonhealing Apexogenesis



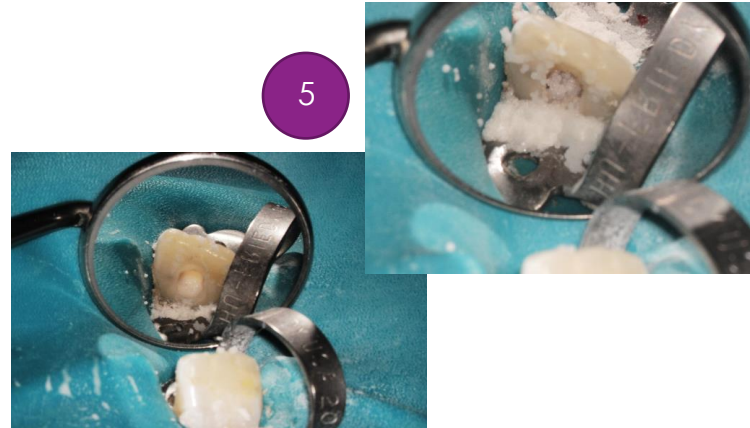10/2015 –
Apexification



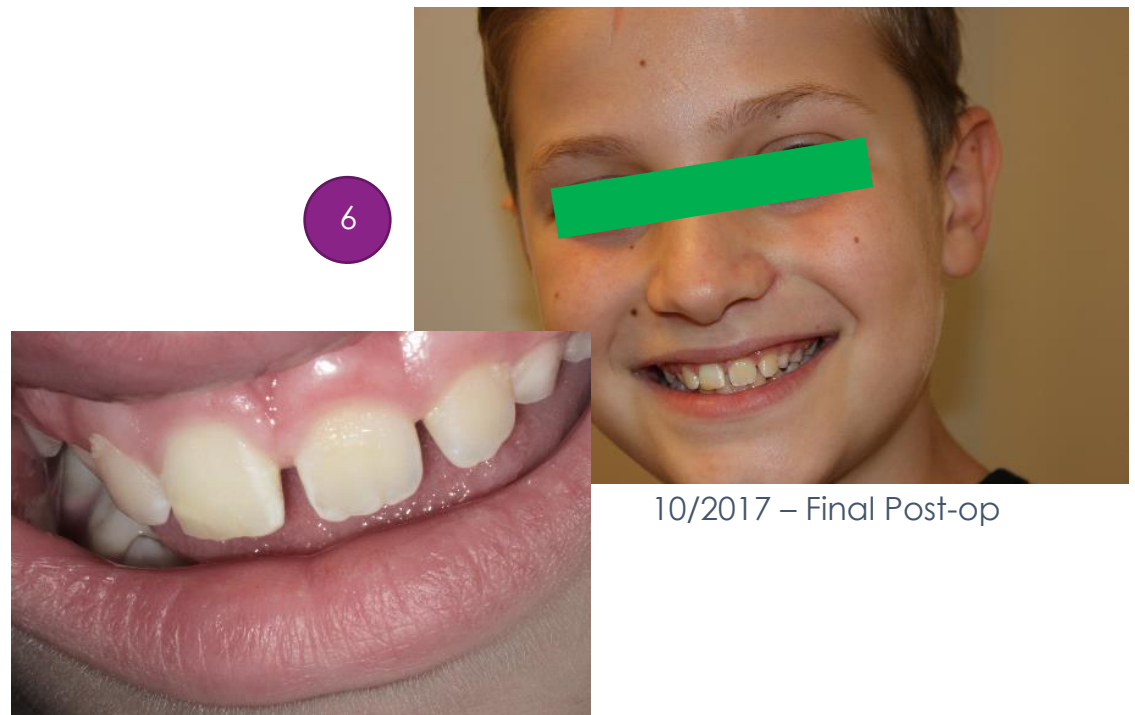
2016 –
Healing



08/2017 –
Healed, small apical scar



09/2017 –
Internal bleaching technique



10/2017 – Final Post-op

ENDO CASE CONTINUED:

This case highlights the importance of saving one's natural teeth and the necessity for a stepwise treatment plan. Despite the non-healing regenerative endodontic procedure, apexification was still a viable treatment option with a favorable prognosis. After 22 months the success of the treatment is visible, and the chief complaint became esthetic. In doing internal bleaching, the young patient was able to keep his natural tooth without the need for aggressive restorative procedures. Traumatized teeth require long-term treatment planning goals and a clear understanding of outcomes. The American Association of Endodontists is currently revising their guidelines for the treatment of traumatic dental injuries, however the publication from 2013 continues to be relevant and is worth a review.

Thank you to the endodontic residents at the University of Maryland School of Dentistry for the documentation and treatment of this happy patient! Case report courtesy of Dr. Lauren Aguilar



Congratulations!

The AAWD BOD would like to congratulate all senior dental students and residents on their incredible accomplishments!

The University of Florida AAWD Student Chapter honored their seniors with a thoughtful graduation gift:



**Want to be featured in the Chronicle Monthly?
Email submissions to aawdchronicle@gmail.com**

THANKS PARTNERS!



ONLINE LEARNING
JOIN US!

June 2 8pmEST
P.U.L.S.E. LEADERSHIP